

## Bovine tunica vaginalis: a new material for umbilical hernioplasty in sheep

B. T. Abass

Department of Surgery and Obstetrics, College of Veterinary Medicine, University of Mosul, Mosul, Iraq  
(Present address: Department of Surgery and Obstetrics, College of Veterinary Medicine, University of Sulaimani, Kurdistan Region, Iraq, E-mail: [drbahjatabbas@yahoo.com](mailto:drbahjatabbas@yahoo.com))

(Received May 28, 2008; Accepted December 16, 2008)

### Abstract

In this study, fresh patches of bovine tunica vaginalis (BTV), was used as implants for the repair of experimentally-created umbilical hernias in eight sheep. The scrotum were harvested immediately after slaughter and thoroughly washed with sterile distilled water for 5-7 times. The scrotal skin together with the fatty tissues and the loose connective tissues and the tunica adventitia were mechanically stripped by means of a sterile surgical knife, and finally washed with sterile physiological saline solution for 5-7 times. The prepared patches were immersed in the sterile saline solution and preserved at 2-4 °C in sterile jars, ready for use within 4 hrs from their harvesting for hernioplasty of sheep umbilical hernias. The eight implanted grafts were examined clinically and histologically, and all were successfully healed except one (87.5%). Clinically, the successfully implanted BTV patches didn't show signs of rejection, except for the presence of cardinal signs of local inflammatory reaction which were subsided 48 hrs post-operation, and disappeared within 4-5 days post-operation. The healing processes showed no significant abnormalities, except for the occurrence of a few simple multifocal stitch abscess infections. The histopathological examinations showed invasion of dense fibrous connective tissues, consisted of heavy bundles of collagen fibers, through which newly formed capillaries and mononuclear inflammatory cells and melanin pigments deposition, were infiltrated through the graft. As a first report on this new tissue implant in sheep, BTV is proved to be a suitable biocompatible heterogenic surgical patch for reconstruction of umbilical hernias, because of its availability as a cheap tissue, with a high tensile strength and flexibility. However, further investigation is required regarding preservation efficiency and employment for reconstruction of soft tissue defects in man and animals.

**Keywords:** Hernia, Sheep, Suture.

Available online at <http://www.vetmedmosul.org/ijvs>

### الغلالة الغمدية للثيران: مادة جديدة للاستخدام كمرقعات لإصلاح فتوق السرة في الضأن

بهجت طيفور عباس

فرع الجراحة والتوليد، كلية الطب البيطري، جامعة السليمانية، إقليم كردستان، العراق

### الخلاصة

في هذه الدراسة، تم استخدام رقع طازجة من غشاء الغلالة الغمدية لخصى الثيران كغرز نسجية لترميم فتوق السرة المستحدثة تجريبياً في ثمان أغنام. وتم جمع أكياس الصفن من خصى الثيران بعد ذبحها مباشرة وتكرار غسلها بالماء المقطر العقيم 5-7 مرات. وتم تحضيرها بإزالة الجلد الصفني وطبقات الدهون والأنسجة الضامة الرخوة وطبقة الغلة الطارئة منها ميكانيكياً باستخدام سكين جراحي عقيم. بعدها تم تكرار غسلها بالمحلول الفسيولوجي السوي وتكرار ذلك 5-7 مرات، وأخيراً حفظها في وعاء عقيم ليتم استخدامها للغرس خلال 4 ساعات في جدار البطن لإصلاح فتوق السرة في أغنام التجربة. تمت متابعة عمليات الغرس بغشاء الغلالة الغمدية لخصى الثيران في ترقيع فتوق السرة في الأغنام سريريا ونسج-أمراضيا ولمدة 90 يوماً. تم فحص الغرس الثمانية سريريا ونسج-

أمراضيا ونجحت جميعها عدا واحدة (٨٧,٥%). وبين الفحص السريري فيها عدم وجود ظواهر الرفض للغرس من قبل جسم المضيف، باستثناء الأعراض الالتهابية الموضعية الأساسية والتي تحسنت بعد ٤٨ ساعة واختفت تماما بعد ٤-٥ أيام. ولم يصاحب مسار التئام الجرح تعقيدات كبيرة تعيق التطور في مراحل الالتئام فيما عدا تولد عدد متفاوت (٢-٤) من البؤر الموضعية الخمجية في موضع الغرز ورشح للسوائل الالتهابية من فتحات الخيوط الجراحية للجلد في موضع العملية والتي تم القضاء عليها بالعلاج الموضعي اليومي والجهازي. وأوضح الفحص النسيجي-المرضي نجاح الالتئام والتمازج التام ما بين الرقع وجسم المضيف. حيث تميزت بغزوها الشديد من قبل النسيج الليفى الكثيف والمتكونة أساسا من حزم ثخينة من الألياف الكولا جينية والتي تخللها الأوعية الشعرية حديثة التكوين والخلايا الالتهابية أحادية النواة ورواسب لصبغة القتامين. وبما أن هذا التقرير هو الأول عن استخدام نسيج الغلالة الغمدية لخصى الثيران للغرس في الخراف. فقد أثبت النسيج ملائمة كرقع نسيجية مغايرة لغرض ترقيع أو ترميم فتوق السرة، لأنها متيسرة كنسيج رخيص وذو قوة شد عالية وقابلة للتكيف في موضع الغرس. ورغم ذلك تبقى الحاجة قائمة للمزيد من البحث والتطوير في طريقة تحضيره وتطبيق استخدامه في ترميم عيوب الأنسجة اللينة للبطن في الإنسان والحيوان.

## **Introduction**

Reconstruction of large abdominal hernias is a difficult surgical problem and commonly encountered as a challenge for the surgeon with recurrence being a common outcome (1-3). As the abdominal wall functions to protect vital intra-abdominal organs, reconstruction of the abdomen carries a higher morbidity rate compared to other cutaneous reconstructive procedures, thus necessitates careful preoperative planning to minimize this risk (4).

Reconstructive options for abdominal wall repair are vast. Numerous methods have been described including; primary repair in one or two layer or Mayo-type overlap, use of fascia (local or flaps) with suture darns; autologous tissue repair; and the use of fascia with synthetic mesh (polypropylene or Marlex mesh, stainless steel, mersiline or expanded polytetrafluoroethylene (3-9). Large hernias (greater than 15 cm) and hernias unsuccessfully repaired previously are often candidates for mesh herniorrhaphy. Polypropylene (Marlex), or the less expensive and less elastic, plastic (Proxplast) mesh products are the most commonly used prosthetics (3). A fascial overlay technique is recommended for placing the mesh (5).

Complications of open abdominal herniorrhaphies remain an important consideration. The most common are; seroma, bowel adhesions and injuries, retro-abdominal abscesses, wound adhesiolysis, and the recurrence of hernia (10,11). In calves, complications of umbilical herniorrhaphy are more numerous than in foals, probably because concurrent infection is more common in calves with umbilical hernias. Most complications are related to incisional problems such as suture abscesses, seromas, hematomas, and dehiscence. The majority of these problems usually do not affect the success of the surgery unless the local infection is severing enough to cause failure of the body wall closure and recurrence of the hernia. Peritonitis is a more serious potential complication (3). The purpose of the present study was to report for the first time in the literature the results of using of bovine tunica

vaginalis (BTV) as implants for the repair of umbilical herniorrhaphy in sheep.

## **Materials and methods**

### **I. Preparation of the BTV:**

The tunica vaginalis were obtained from the scrotum of 1- to 2- years-old male cattle slaughtered under veterinary supervision. The scrotums were harvested under clean but not sterile conditions immediately after slaughter. The scrotums were thoroughly rinsed in sterile distilled water. The skin, smooth muscles, and the tunica dartos were gently striped off with sterile surgical knife. The remaining tunica vaginalis fibrous sheath was repeatedly re-rinsed, for at least 5- to 7- times, with a sterile physiological saline solution (PSS). The prepared layers of tunica vaginalis tissue was stored in a sterile glass jars, bathed in sterile PSS, and stored at 2- to 4- °C. The prepared tissue was ready for hernioplasty procedure within 4- to 6- hours post-collection and preparation.

### **II. Experimental animals:**

Eight physically healthy adult non-pregnant female sheep, aged 12- to 16- months (Mean  $\pm$  SE = 13  $\pm$  4.7 months), and body weight 20- to 26- kg (22.4  $\pm$  6.2 kg), were used. The animals were ear tagged and housed indoor under the same feed and management conditions.

### **III. Experimentally inducing umbilical hernia:**

Induced umbilical hernia was created, in all experimental sheep. Each animal was fastened for, 24 hours from food and 12 hours from water, prior to surgery. The skin at the ventral abdominal region, from the xyphoid to the pubic symphysis, was prepared for aseptic surgery. General anesthesia was induced by premedication, with atropine sulphate (0.2 mg/kg, intramuscularly), followed by induction of anesthesia intravenously by a mixture of xylazine HCl (0.05 mg/kg) and ketamine HCl (4 mg/kg). The air-way was protected by stomach intubations. The animal was placed on dorsal recumbency and draped with surgical clothes. A mid-line, 10 cm length, skin incision

was made at the umbilical region. The skin was bluntly dissected from the under-laying connective tissues. The linea alba was incised for about the whole length of the skin incision, to expose the peritoneum and the abdominal cavity. The peritoneum was excised at umbilicus and the regional retroperitoneal fat was removed. Two elliptical incisions were made on either sides of the abdominal muscles (aponeurosis of the transversus muscle which is the internal lamina of the sheath of the rectus abdominus muscles) at the umbilical region, and a circular piece of 3- to 4- cm in diameter from the muscles was removed. Following hemostasis, the circular edges of the incised muscles was sutured by simple continuous mattress suture, using 0 USP polygalactin, so as to produce an artificial hernial ring. Finally the skin was closed with 1 USP silk, using interrupted suture. Daily wounds management and dressing was practiced post-operatively and the ventral abdominal area at the umbilical region was supported by a cloth-made belt for 2 weeks. The skin stitches were removed at the 10<sup>th</sup> post-operative day, and the animals were followed for one month for the development of umbilical hernia, which was successfully developed in all experimental sheep.

#### IV. Hernia Repair with BTV patch grafts:

1. About the 30<sup>th</sup> day ( $\pm$  3 days) post the experimental creation of hernias, each sheep was prepared for the procedures of hernioplasty using the freshly prepared patch of BTV. Prior to surgery, the animal was fastened from food for 24 hrs and from water for 12 hrs and was subjected to a course of umbrella antibiotics. Penicillin – streptomycin (10,000 I.U./kg and 10 mg/kg, respectively), intramuscularly was administered 12 hours prior to surgery, and once every 24 hours for the next 5 days post operation.
2. The pre-operative surgical preparations and anesthetic procedures were similar to those followed and described during creation of umbilical hernias. All the repaired umbilical hernias were reducible once with a clear palpable hernial ring. A skin incision over the umbilicus was made over the hernial sac, and bluntly dissected from the hernial sac. The hernial sac was opened and excised across the scarred edge of its ring by sharp incision together with the peritoneum which was usually found adhered to the limit of the hernial ring. The peritoneum was closed by 2-0 USP polygalactin, using interlock suture. A suitable size of BTV patch, with its visceral surface facing the abdominal cavity, was threaded securely and circumferentially to the edge of the excised hernial ring by 1-0 USP polygalactin using interrupted suture. The expanded umbilical skin flap was trimmed to tightly cover the BTV patch graft and was closed routinely by No. 1 USP silk suture.

#### V. Post-operative care and clinical Examination:

A daily postoperative wound care follow-up was carried out for two weeks after operation. This included; cleaning, wound spraying and dressing with sterile gauze, in addition to the physical and general health status of the animal (body temperature, appetite, and defecation). The operated animal was then clinically examined, by visual inspection and manual palpation at the umbilicus, every week for the following three months.

#### VI. Biopsy collection for histopathological examination:

Biopsies were collected from the experimental animals at 15, 30, 60, and 90 days after hernioplasty with the BTV patch graft. The sampling procedures were conducted while the animals were under the effect of sedation and local infiltration analgesia. A wedged tissue specimen was collected aseptically from the periphery of hernioplasty. The specimens were fixed in 10% formalin solution for 48 hours, trimmed to suitable sizes, washed, dehydrated, cleared in Xylol, embedded in Paraffin Wax, sectioned at 5-6 microns thickness, stained with Hematoxylin and Eosin, and examined with a light microscope (12).

### Results

#### I. Clinical findings:

The cardinal signs of inflammation, (i.e., swelling, heat, pain, redness and tenderness) were seen locally at the site of hernioplasty. These signs were gradually subsided, particularly from 48 hrs post-operation onward, and disappeared within after 4-5 days. Decreased body activity and anorexia was found in all sheep during the first 48 hrs following hernioplasty. At the end of the first post-operative week, a thick and slightly hard mass of tissue of about 1- to 1.5- cm in thickness and its size corresponded to the size of the implanted BTV graft was palpated at the site of operation. The skin wound in all eight experimental sheep was healed by first intention, except in one, and the skin stitches were removed at the 10<sup>th</sup> post-operative day. Some stitches abscesses and/or small necrotic foci from were exudates was discharging were usually seen at the site of the hernioplasty. But these sinus tracts were well responding to the treatment applied locally, i.e., by cleaning and debridement of site, and local injection of 1% solution of tincture of iodine, except for one sheep (No. 6). The latter case showed failure of hernioplasty (12.5%) at the 17<sup>th</sup> postoperative day, due to the septic inflammation at the site of operation which lead to necrosis of the implanted BTV, wound dehiscence and re-herniation which was successfully treated, latter on, by suture repair technique. The thick and hard mass of tissue at the site of operation was palpable till the end of the 2<sup>nd</sup> to 3<sup>rd</sup> post-operative week. These masses were all largely subsided by the end of the 4<sup>th</sup> postoperative week. They were replaced by a very thin and small piece of fibrous tissue which was difficultly

felt after the 4<sup>th</sup> postoperative week (29-35 days). All signs of swelling or inflammation were disappeared in the herniorrhaphy successive seven sheep at end of the 3<sup>rd</sup> week, post operation. The umbilical regions was looked normal on inspection, the skin over the patch graft adhered firmly to the underlying tissue and looks healthy and non painful on firm and deep palpation. Macroscopically, during biopsy collection, at 30 days following surgery, a sandwich-like cover with a thin membrane was observed on the patch grafts. At the 60-90 days the implants were found firmly adhered to the host tissues and with good interposition and vascularization.

## II. Histopathologic Findings:

Histopathological examination of the BTV patch grafts at the 15<sup>th</sup> post-implantation day revealed presence of granulation tissue consisted mainly of bundles of collagen fibers which were infiltrated by mononuclear inflammatory cells represented by macrophage and plasma cells. These were surrounding the remnants of suture materials (Fig. 1). Loose connective tissue was also presented which consisted

of bundles of collagen fibers highly vascularized (proliferation in capillaries) with deposition of fibrin (Fig. 2). Some sections elucidate presence of inflammatory nodules consisted of high numbers of neutrophiles and presence of thrombus. At 30<sup>th</sup> post-operative days, the histopathological sections showed a reduction in the inflammatory nodules and remnant suture material was surrounded by collagen fibers infiltrated by macrophages and plasma cells (Fig. 3). In addition to presence of dense connective tissue, which consists from heavy bundles of collagen fibers, there was a new cappillarizing, infiltration of mononuclear inflammatory cells and congestion of blood vessels as well melanin pigment deposition (Fig. 4). At 60<sup>th</sup> post-operative day, an excellent intermingling between the BTV patch and the original surrounding tissue was seen. There was an increased infiltration of connective tissue within a mature fibrous tissue with a relatively fewer inflammatory cells (Fig. 5). At the 90<sup>th</sup> days, infiltration of dense connective tissue and a decreased neovascularization was observed.

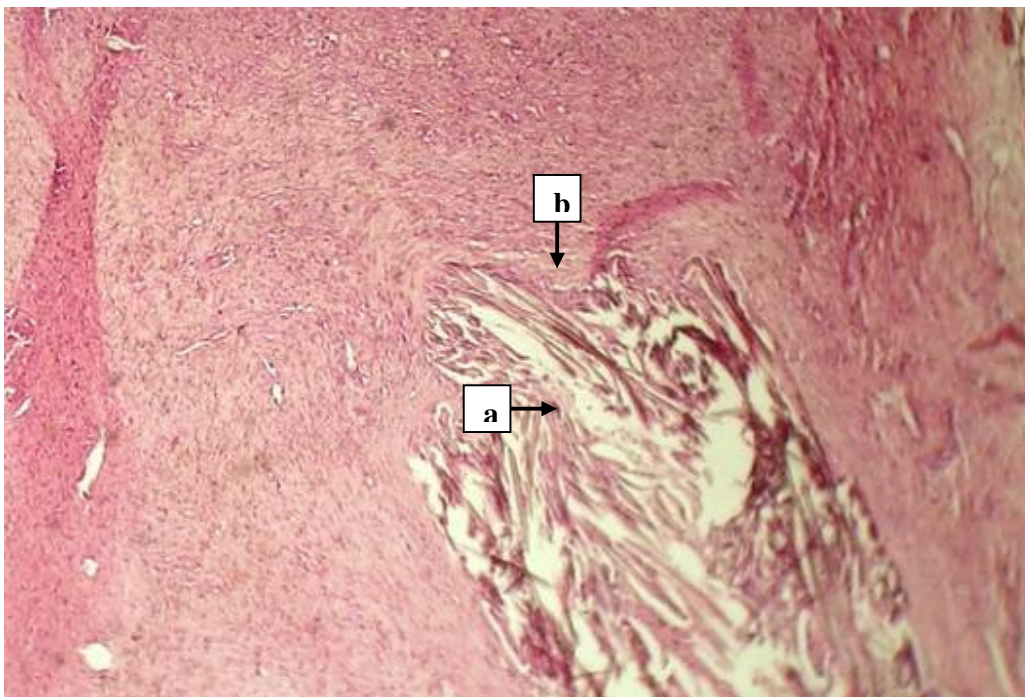


Figure 1: Histomicrograph of BTV patch graft 15 days after implantation for umbilical hernioplasty in sheep, showed presence of remnant of suture material surrounded by collagen fibers (a-arrow), and mononuclear inflammatory cells (b-arrow). HE stain, 100 x.

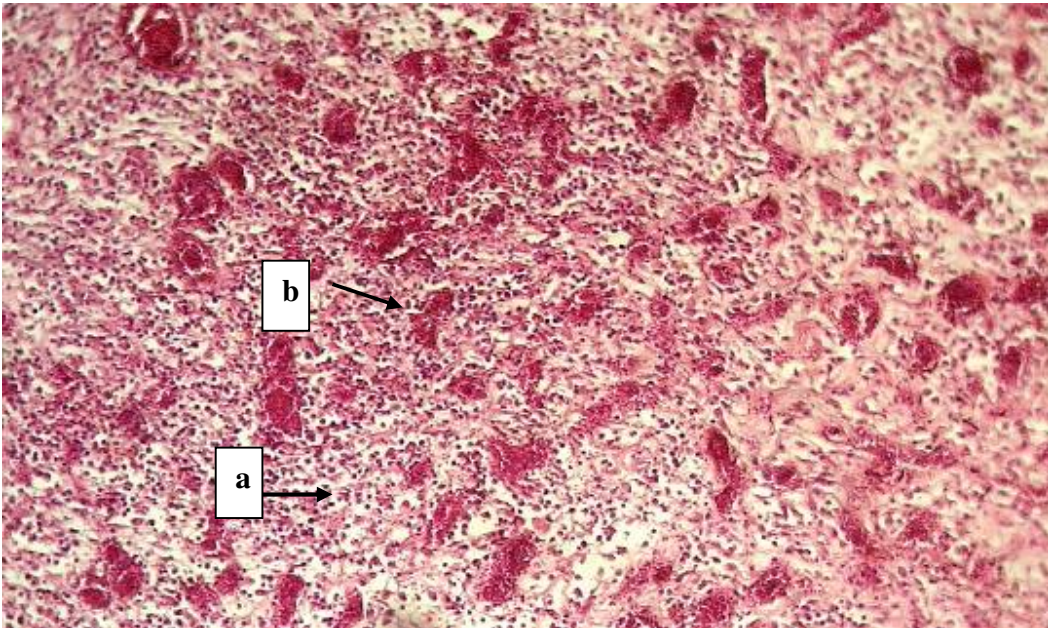


Figure 2: Histomicrograph of BTV patch graft 15 days after implantation for umbilical hernioplasty in sheep, showed presence of granulation tissue (a), and loose connective tissue a highly vascularize with newly formed capillaries (b). HE stain, 400 x.

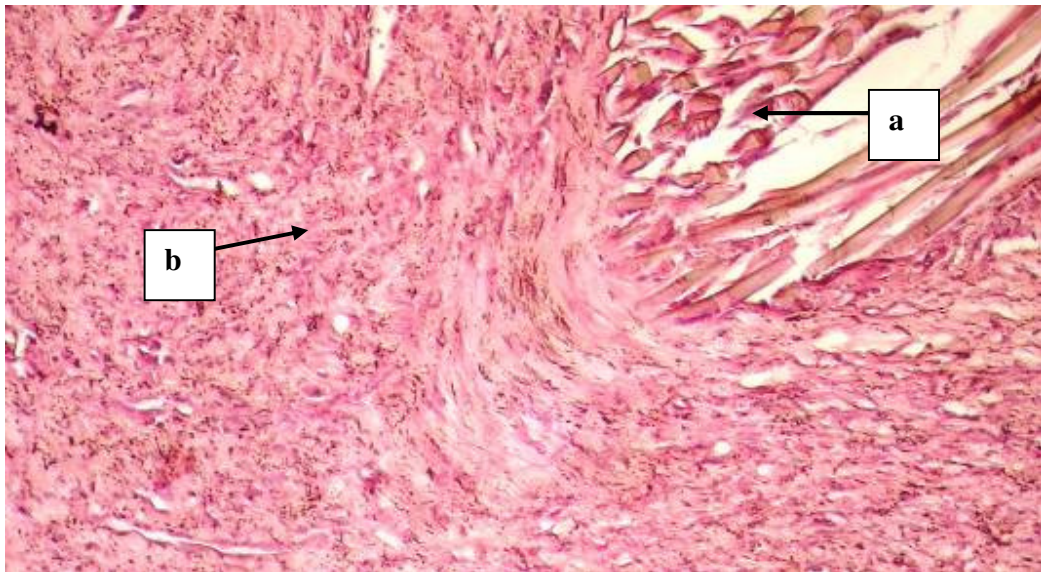


Figure 3: Histomicrograph of BTV patch graft 30 days after implantation for umbilical hernioplasty in sheep, showed reduction in remnant suture material (a), and infiltrated by macrophage cells (b). HE stain, 100 x.

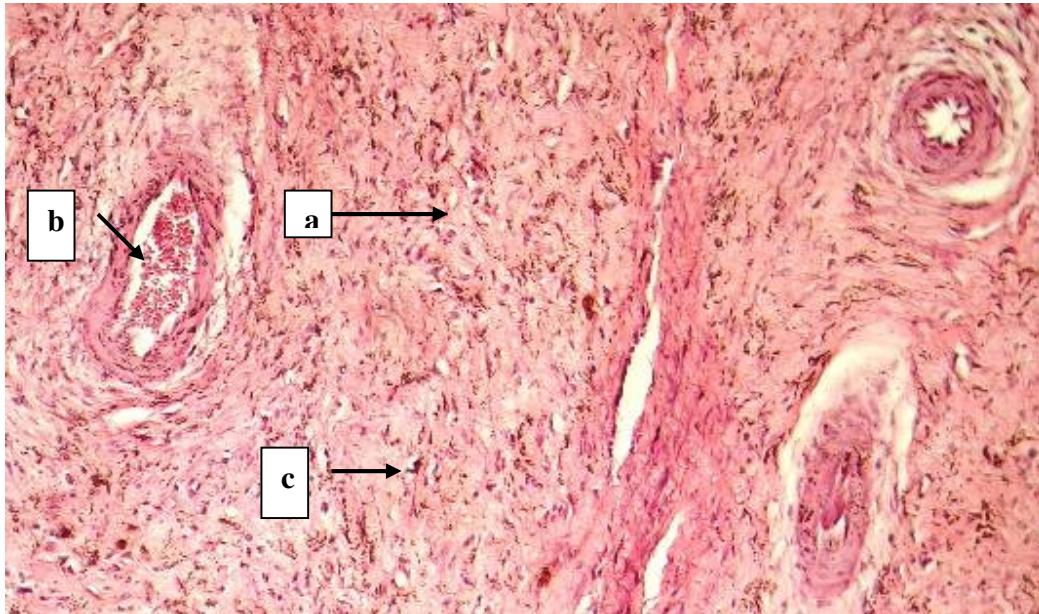


Figure 4: Histomicrograph of BTV patch graft 30 days after implantation for umbilical hernioplasty in sheep, showed increased infiltration of dense connective tissue (arrow), consisted from collagen fibers (a) newly capillaries (b) and melanin pigment (c). HE stain, 400 x.

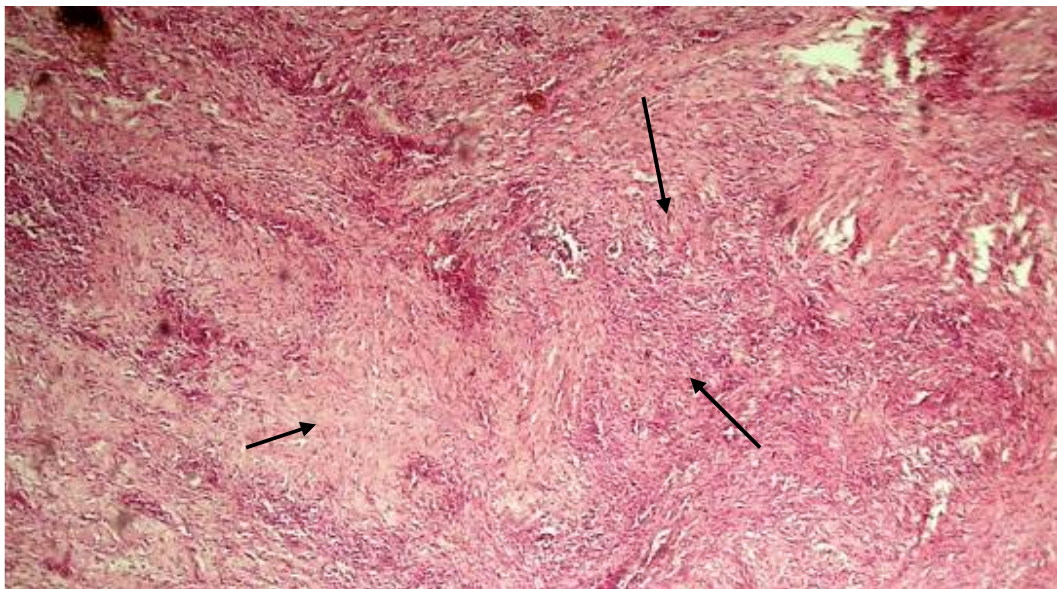


Figure 5: Histomicrograph of BTV patch graft 60 days after implantation for umbilical hernioplasty in sheep, showed a relatively fewer inflammatory cells with an increased infiltration of the connective tissue was observed (arrow). HE stain, 100 x.

## **Discussion**

In this study observation of implanted BTV patches three months after surgery showed that there were little local inflammatory reaction, and satisfactory tissue affinity after implantation. The tissue was proved to be a good hernioplastic patch, because of its workability, flexibility, reduced thickness, and cost effectiveness, allogeneous biomaterial substitute. Search for an ideal artificial or natural biomaterial substitute used to graft acquired or congenital abdominal wall defects is a challenge. The ready availability of non-immunogenic and non-prosthetic biomaterial that could guide the regeneration of normal tissue is a fascinating possibility. Many biomaterials are already in use: muscle flaps (13); acellular matrix (14); redundant skin as autograft (7); autogenous fascia lata graft (8); pericardium (15,16); and tunica vaginalis (16). Tunica vaginalis biomaterial has been used for urethral reconstructions in humans (17,18), with disappointing results, referred to the urethral stricture, but not to the rejection of the patch grafts in all cases (17). In contrast, Kader, *et. al.* (16) was the first to describe the use of tunica vaginalis patch grafts to repair umbilicus hernias in sheep with high success. The implanted alloplast tissue produced extremely favorable affinity to the host tissues as it was difficult to identify the grafts at 90 postoperative days (16). In the present investigation the results indicate that BTV patch grafts used for hernioplasty, produced an extremely favorable affinity to body tissues, and was much similar to the results of umbilical hernioplasty in sheep by ovine tunica vaginalis (OTV) patch grafts (16). Although the implanted BTV is considered as heterograft, while the OTV is homograft, but doesn't showed evidence of tissue rejection possibly because both of them share similar biological properties. As they are flask-like fibro-serous sac which is continuous with the parietal peritoneum of the abdomen at the internal inguinal ring and extends through the inguinal canal to the bottom of the scrotum, consists of two layers- parietal and visceral (19).

For surgical repair of abdominal hernias using prosthesis; 1) appropriate surgical repairing technique; 2) durability of the material; 3) tissue compatibility; 4) ease of suturing; 5) preservation method of material; 6) and cost (20), are important points for consideration to select a material which has less probability of being rejected, less tissue reactions and no harmful effects to other organs. The procedural phases used for preparation of BTV patches, although were simple, but was effective as an important outcome in the success of the patch as a new material for hernioplasty. The only single case of hernioplasty failure with BTV (one out of eight, i.e., 12.5%) is considered as a very good result. In a review of the literature, Houck and colleagues (21) reported the rate of infection after incisional hernia repair, with and without prosthesis, to range from

15% to 45%, and expressed the view that these procedures should be considered "contaminated" for surveillance and reporting purposes. Although umbilical hernia may differ from incisional hernia etiology, but treatment modalities for ventral hernia repair are similar and results may be compared (22). We believe the unsuccessful repair in the only one hernioplasty case was not due to the implanted tissue rejection, but to the contamination and the large seroma accumulated at the site of herniorrhaphy, which produced wound infection lead to erosion of the patch and wound dehiscence with reherniation. The careful separation between the rough parietal tunica vaginalis layer and the tougher tunica adventitia, during the initial steps of tissue processing, lead to the harvesting of fine patches which were rated in size from about 100 cm<sup>2</sup> to 150 cm<sup>2</sup>. It was important during the harvesting process of the tunica vaginalis (mesothelium plus a thin layer of loose connective tissue) not to scratch the serosal surface and /or to hole the patch, which was rejected if so. Because the patch was implanted with its serosal surface against the bowel, and scratches or holes could enhance adhesion between the patch and the bowel viscera. Although we didn't search for the formation of adhesion between the patch and the internal organs at the site of hernioplasty, but it will worth to study the rate of its occurrence in a future plane study. The prepared patches were not sterile, but believed to be clean, because they were collected under strict veterinary supervision, directly after death of calves, and their scrotal skin was removed directly after their thorough wash with the sterile distilled water, then rewashed and transferred into sterile jars bathed in saline solution and transported in refrigerated cool box to the laboratory, where finalization of the process was completed to render the patch ready for instant hernioplasty. The encountered 87.5% success in the BTV hernioplasty as deemed from the post-surgical results for absence of evidence of peritonitis, septicemia, or graft rejection and wound dehiscence confirm our conclusion on rendering the patches clean and safe for implantation. While, the sinus tract or multiple focal infections, were usually encountered in most of the hernioplasted sheep, and were controlled by treating them routinely as applied for stitch abscesses by cleaning and local antiseptic injection into the tracts, in addition to the systemic use of broad-spectrum antibiotics.

In conclusion, the quality of the results obtained from the clinical and histopathological standpoints, as well as in terms of tolerance, together with the simplicity of the patch graft preparation and its costeffectiveness, has led us to consider it as a good method in repair of hernias.

We suggest that BTV grafts, as a natural biomaterial substitute, is a comparatively satisfactory material for the closure of abdominal wall defects and have potential clinical applications for hernioplasty in man and animals.

## **Acknowledgement**

This study was supported by the College of Veterinary Medicine, University of Mosul.

## **References**

1. Langer S, Christiansen J. Long-term results after incisional hernia repair. *Acta Chir Scand* 1985; 151: 217.
2. Burger JWA, Luijerdijk RW, Hop WCJ, Halm JA, Verdaasdonk EGG, Jeekel J. Long-term followup of a randomized controlled trial of suture versus mesh repair of incisional hernia. *Ann Surg* 2004; 240 (4): 578-585.
3. Baxter GM. Hernias/Umbilicus. In: *Farm animal Surgery*. Fubini SL, Ducharme NG. Missouri; Saunders 2004. pp: 477-484.
4. Wilhelmi JB, Mowiavi A, Neumeister M, Zook EG. Abdominal wall reconstruction. *eMedicine.com, Inc.* 2005: 1-12.
5. McIlwraith CW, Robertson JT. Herniorrhaphy using synthetic mesh and fascial overlay. In: *Equine surgery advanced techniques*, ed 2, Philadelphia, 1998, Williams & Wilkins, pp: 365-370.
6. Giroto JA, Chiaramonte M, Menon NG, Singh N, Silverman R, Tufaro AP, Nahabedian M, Goldberg NH, Manson PN. Recalcitrant abdominal wall hernias: long-term superiority of autologous tissue repair. *Plas Reconstr Surg* 2003; 112 (1): 106-114.
7. Sebanti G, Supratic C, Sudhir A, Mamta S. Use of redundant skin as autograft in repair of incisional hernia. *J Obstet Gynecol Ind* 2004; 54 (4): 393-394.
8. Bongartz A, Carofiglio F, Balligand M, Heimann M, Hamaide A. Use of autogenous fascia lata graft for perineal herniorrhaphy in dogs. *Vet Surg* 2005; 34: 405.
9. Bauer JJ, Harris MT, Kreef I, Glerent IM. Twelve-year experience with expanded polytetrafluoroethylene in the repair of abdominal wall defects. *Med Surg J* 1999; 66 (1): 20-25.
10. Khaira HS, Lall P, Hunter B, Brown JH. Repair of incisional hernias. *J R Coll Surg Edinb* 2001; 46: 39-45.
11. Heniford BT, Park A, Ramshaw BJ, Voeller G. Laparoscopic repair of ventral hernias. *Ann Surg* 2003; 238 (3): 391-400.
12. Drury RA, Wallington EA, Cameron SR. *Carleton's histological technique*, 4<sup>th</sup> ed., Oxford University Press, London. 1967, Pp: 35, 49-59.
13. Philibert D, Fowler JD. Use of muscle flaps in reconstructive surgery. *The Compendium* 1996; 13 (4): 395-404.
14. Gamba P, Conconi M, Lo Piccolo R, Zara G, Spinazzi R, Parnigotto P. Experimental abdominal wall defect repaired with acellular matrix. *Pediatric Surg International* 2002; 18 (5-6): 327-331.
15. Mazzanti A, Raiser AG, Pippi NL, et al. Diaphragmatic hernioplasty in dogs with bovine pericardium preserved in supersaturated sugar solution. *Arq Bras Med Vet Zoo Tec* 2003. 55 (6): 677-684.
16. Kader NH, Abass BT, Al-Sadi HI. A comparative experimental study of the use of tunica vaginalis and pericardium as allograft for hernioplasty in sheep. *Iraqi J Vet Sci* 2005; 19 (1): 57-70.
17. Joseph DB, Perez LM. Tunica vaginalis onlay urethroplasty as a salvage repair. *J Urology* 1999, 162: 1146-1147.
18. Theodorescu D, Balcom A, Smith CR, McIlorie GA, Churchill BM, Khoury AE. Urethral replacement with vascularized tunica vaginalis: defining the optimal form of use. *J Urology* 1998, 159: 1708-1711.
19. Sissons and Grossman J D. *The anatomy of the domestic animals*. W.B.Saunders Co., 4<sup>th</sup> ed. Philadelphia. 1953. pp: 584-586.
20. Matsumoto H, Oguchi Y, Miyake Y, Masuda Y, Masada S, Kuno Y, Shibahara I, Takashima K, Yamane H, Yamagata S, Noishiki Y, Yamane Y. The use of epoxy patch grafts for the repair of experimentally-created diaphragmatic defects in dogs. *G Vet Med Sci* 1996; 58 (7): 685-687.
21. Houck JP, Rypins EB, Sarfeh II, et al. Repair of incisional hernia. *Surg Gynecol Obstet* 1989; 169: 397-399.
22. Burger JAW, Luijerdijk RW, Hop WCJ, Halm JA, Verdaasdonk EGG, Jeekel J. long-term follow-up of a randomized controlled trial of suture versus mesh repair of incisional hernia. *Ann Surg* 2004; 240 (4): 578-585.